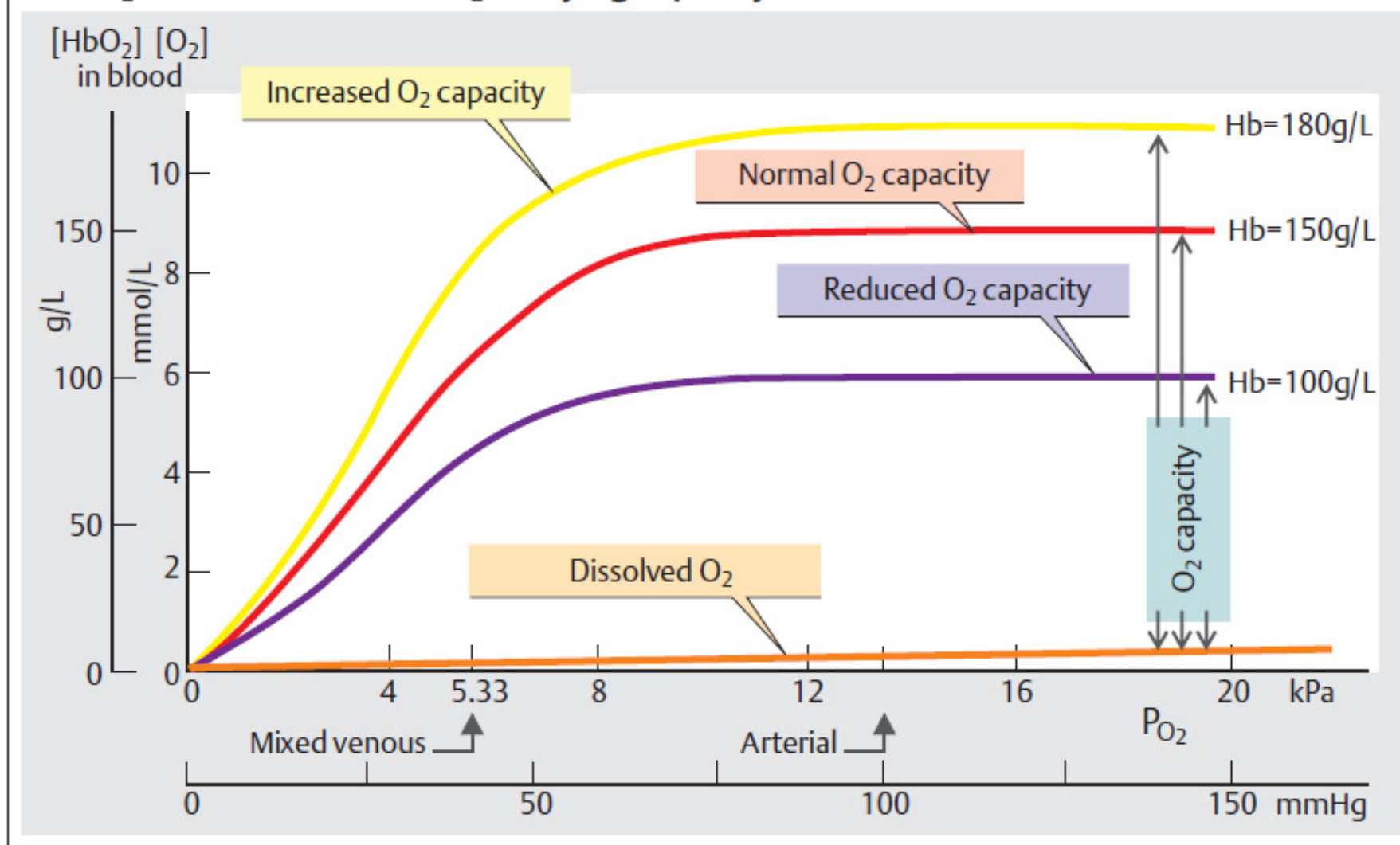


Hematologická vyšetření 2

Blood volume (L)	♂ $0.041 \cdot \text{kgKG} + 1.53$;	♀ $0.047 \cdot \text{kgKG} + 0.86$
Hematocrit ($L_{\text{cells}}/L_{\text{blood}}$)	♂ 0.40 – 0.54;	♀ 0.37 – 0.47
Number ($10^{12}/L_{\text{blood}} = 10^6/\mu\text{L}_{\text{blood}}$)	♂ 4.6 – 6.2;	♀ 4.2 – 5.4
Hemoglobin (g/ L_{blood})	♂ 140 – 180;	♀ 120 – 160
Number ($10^9/L_{\text{blood}} = 10^3/\mu\text{L}_{\text{blood}}$)	3 – 11 (of which 63% granuloc., 31% lymphoc.,	
Number ($10^9/L_{\text{blood}} = 10^3/\mu\text{L}_{\text{blood}}$)	♂ 170 – 360;	♀ 180 – 400 \6% monoc.
(g/l Serum)	66 – 85 (of which 55 – 64% albumin)	

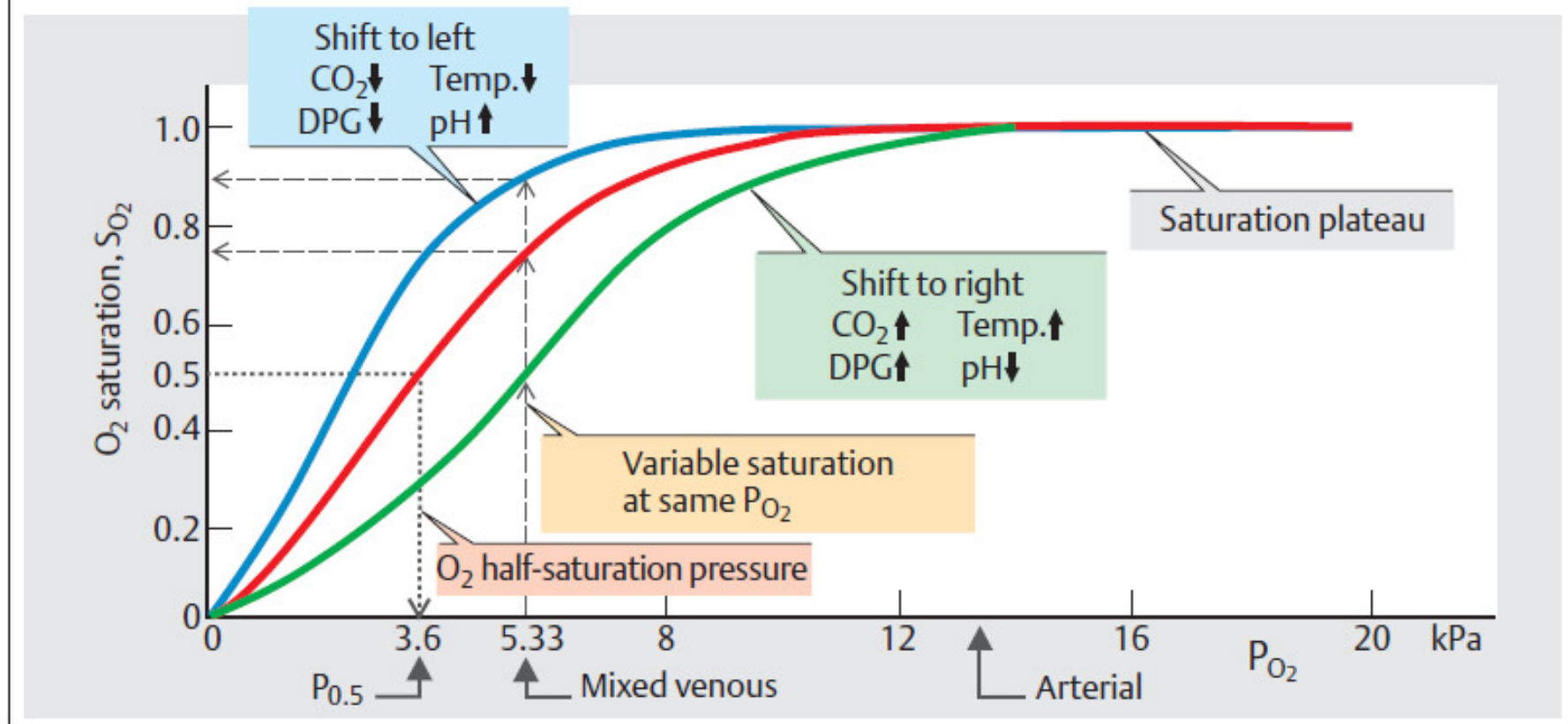
připomenutí hodnot + 1 regresní rovnice

A. O₂ dissociation curve: O₂-carrying capacity



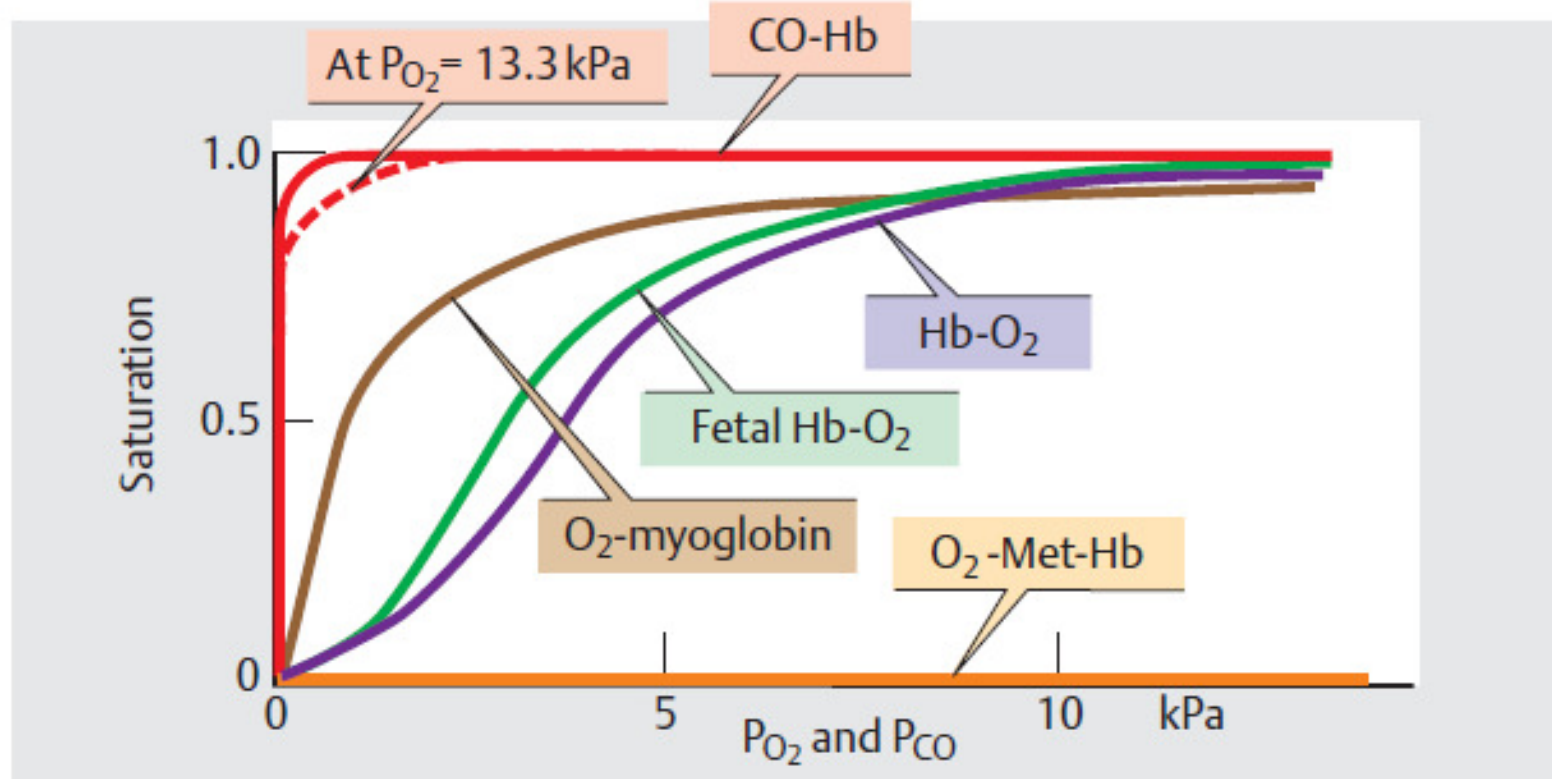
krevní plyny – kyslík/ (CO₂ je podobný)

B. O₂ dissociation curve: O₂ saturation



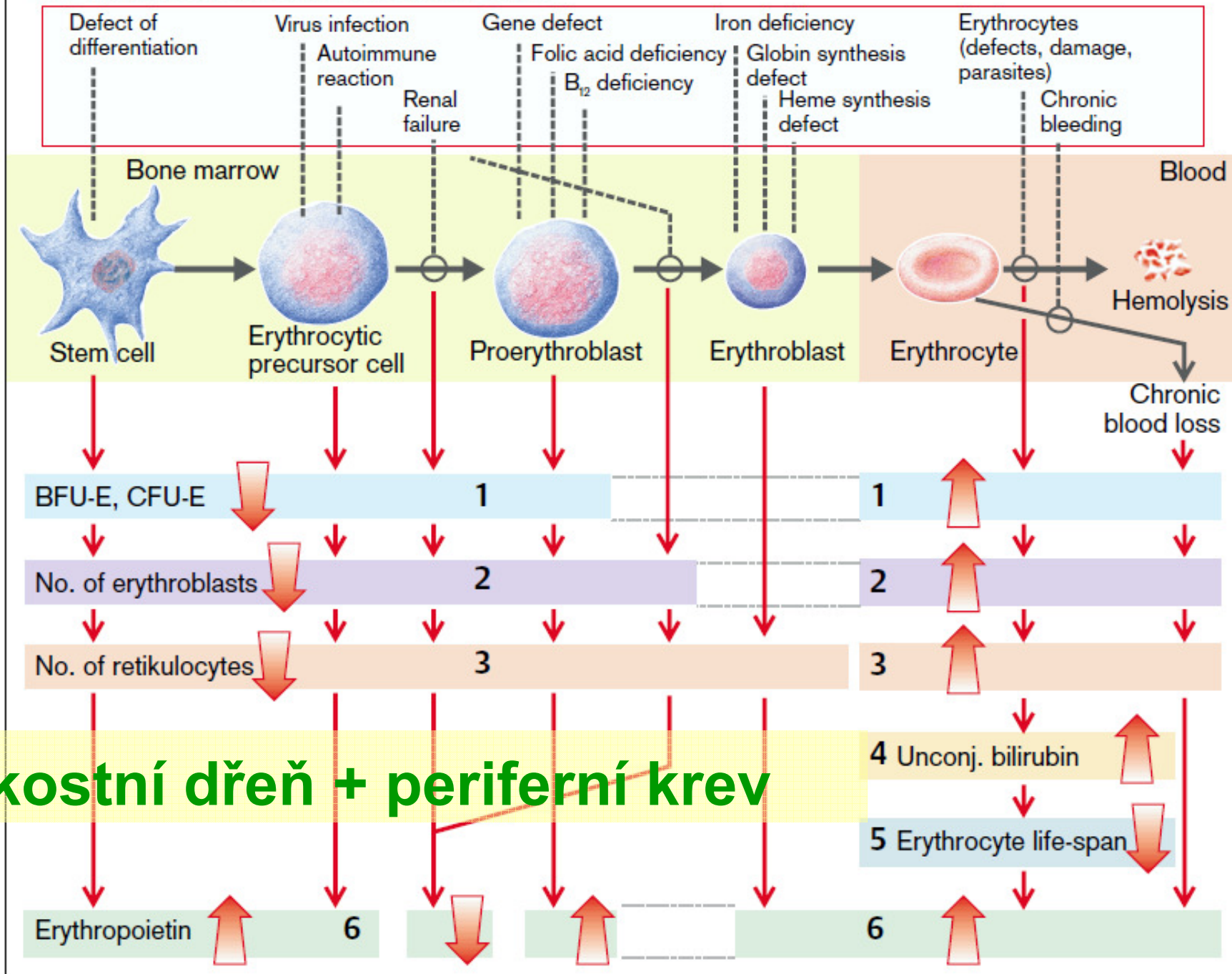
kyslík - saturační křivka

C. O₂ and carbon monoxide (CO) dissociation curves



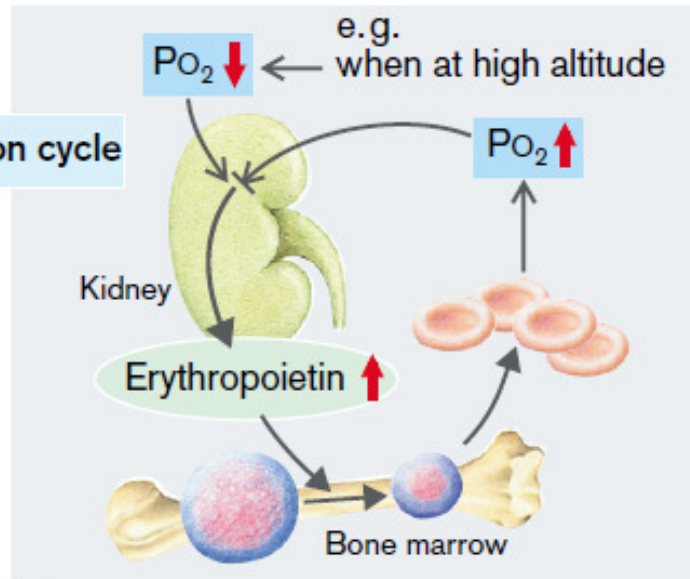
myoglobin a další varianty hemoglobinu

A. Diagnostic Parameters in Anemia

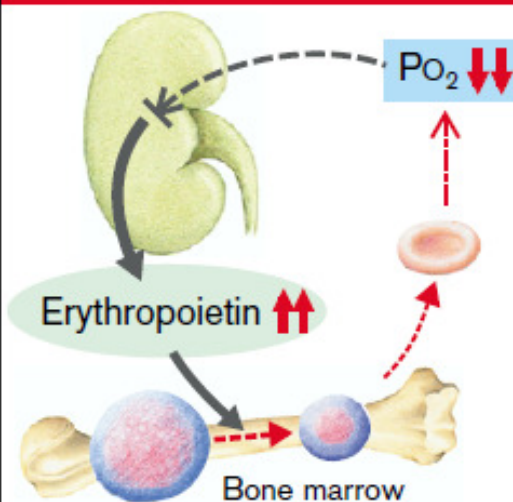


B. Erythropoietin Concentration as Anemia Indicator

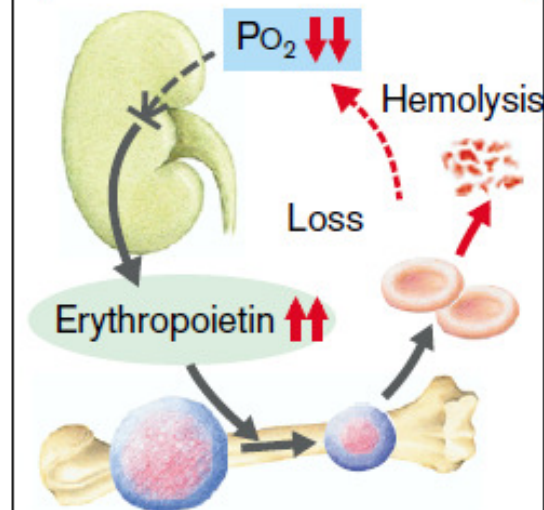
1 Normal regulation cycle



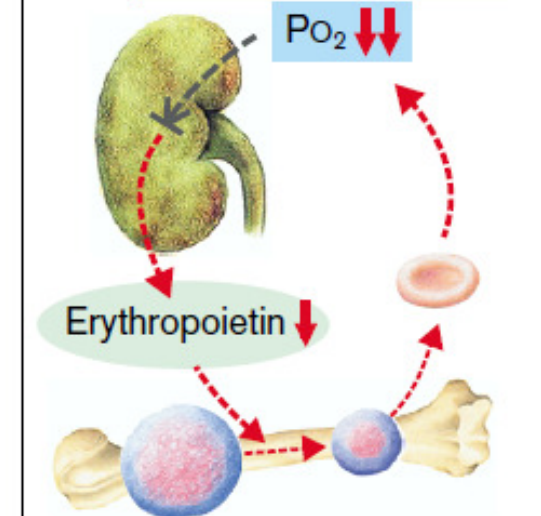
2 Abnormality of erythrocyte or hemoglobin formation



3 Hemolysis, blood failure

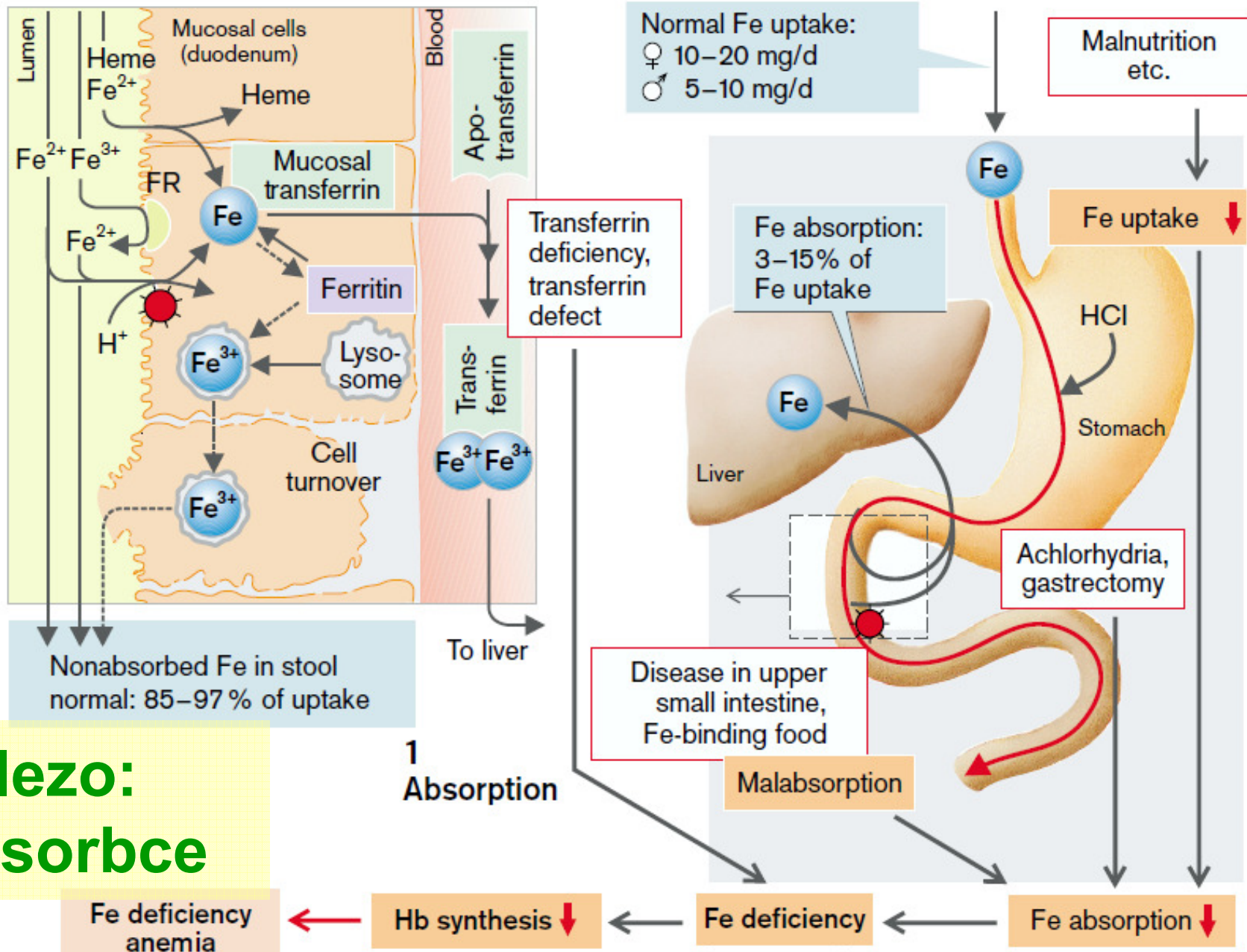


4 Renal failure

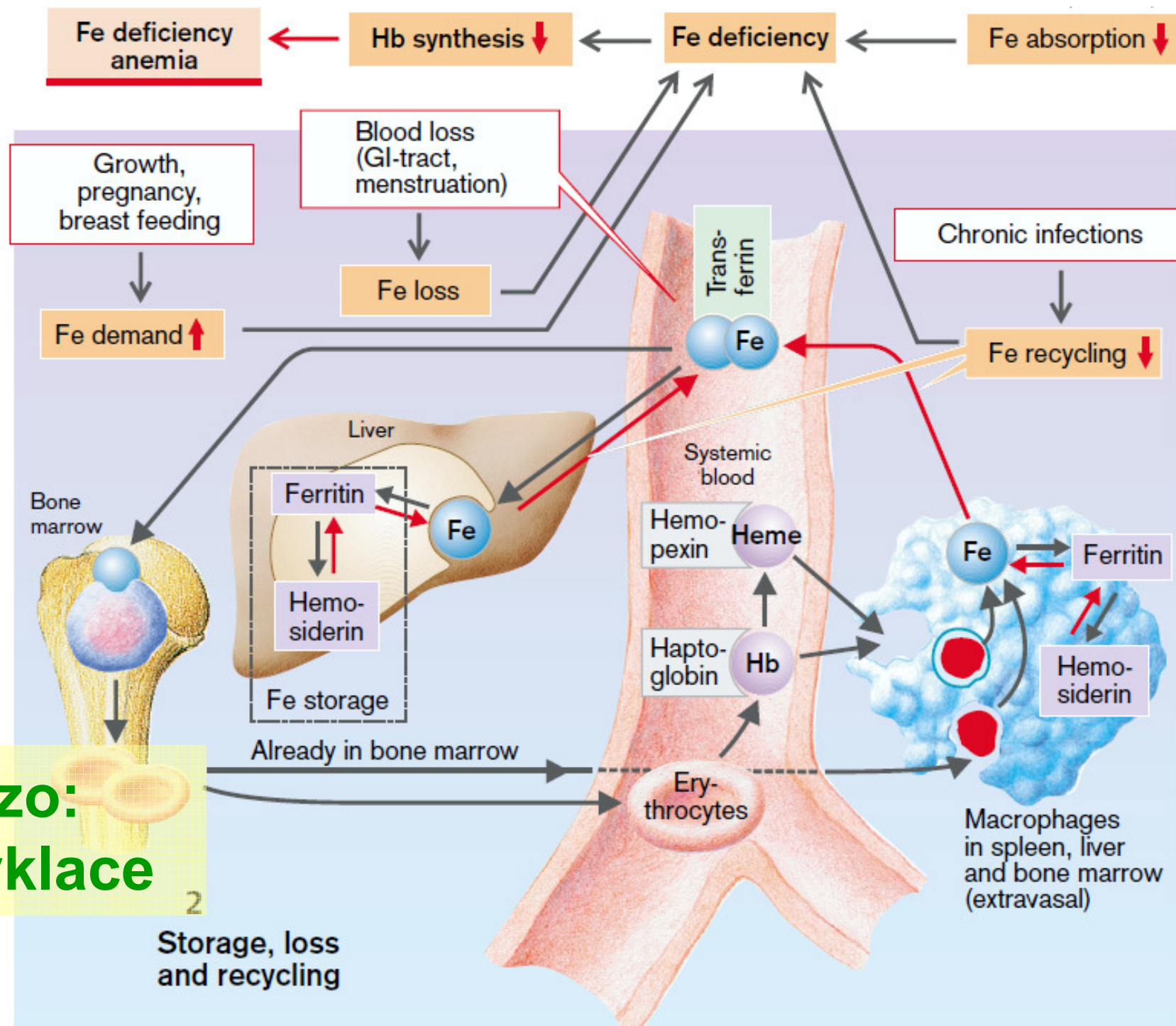


Erythropoietin

A. Iron (Fe) Deficiency Inhibits Hemoglobin Synthesis



železo:
absorbce



železo:
recyklace

A. Hemochromatoses

1
Primary hemochromatosis
inherited autosomal
recessive disease
(Cys-282-Tyr mutation
in 83% of patients)

2
Secondary hemochromatoses
ineffective erythropoiesis, chronic
liver diseases, porphyria cutanea tarda,
parenteral Fe overloading, etc.

Raised Fe absorption

Hemochromatosis
Fe content ↑ (from 2–6g to >50g!)

Treatment

Venesection
(0.5g Fe/L of blood)

Fe toxicity: lipid peroxidation, DNA damage, collagen formation ↑

Liver:

Siderosis

Fibrosis

Cirrhosis

Carcinoma

Pancreas:

Siderosis

Fibrosis

Diabetes mellitus

Skin:

Incorporation of
melanin and
hemosiderin

Pigmentation

Heart:

Siderosis

Cardiomyopathy

Arrhythmia

Heart failure

Joints:

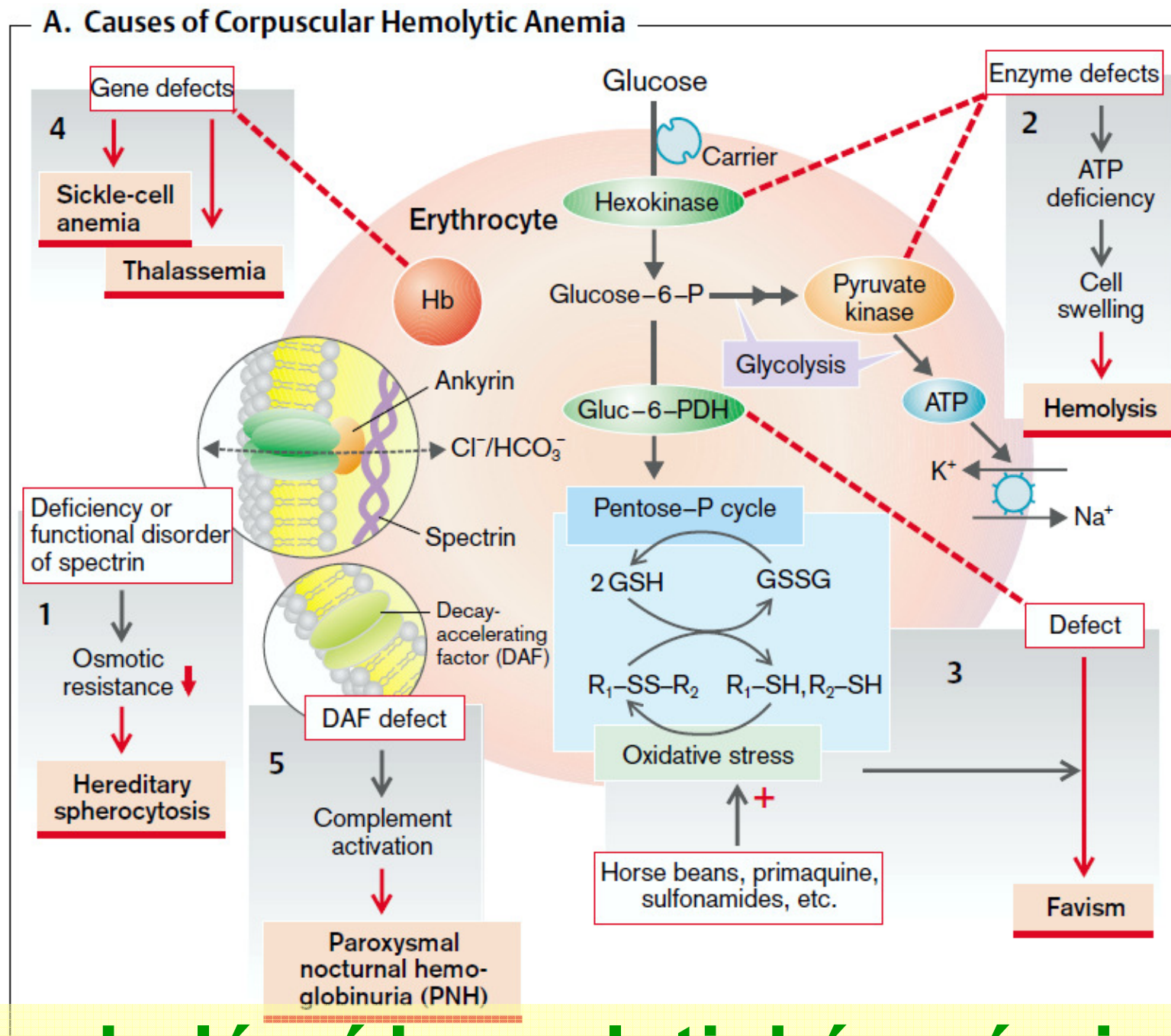
Vitamine C
deficiency

Pseudogout

Testes:

Infertility

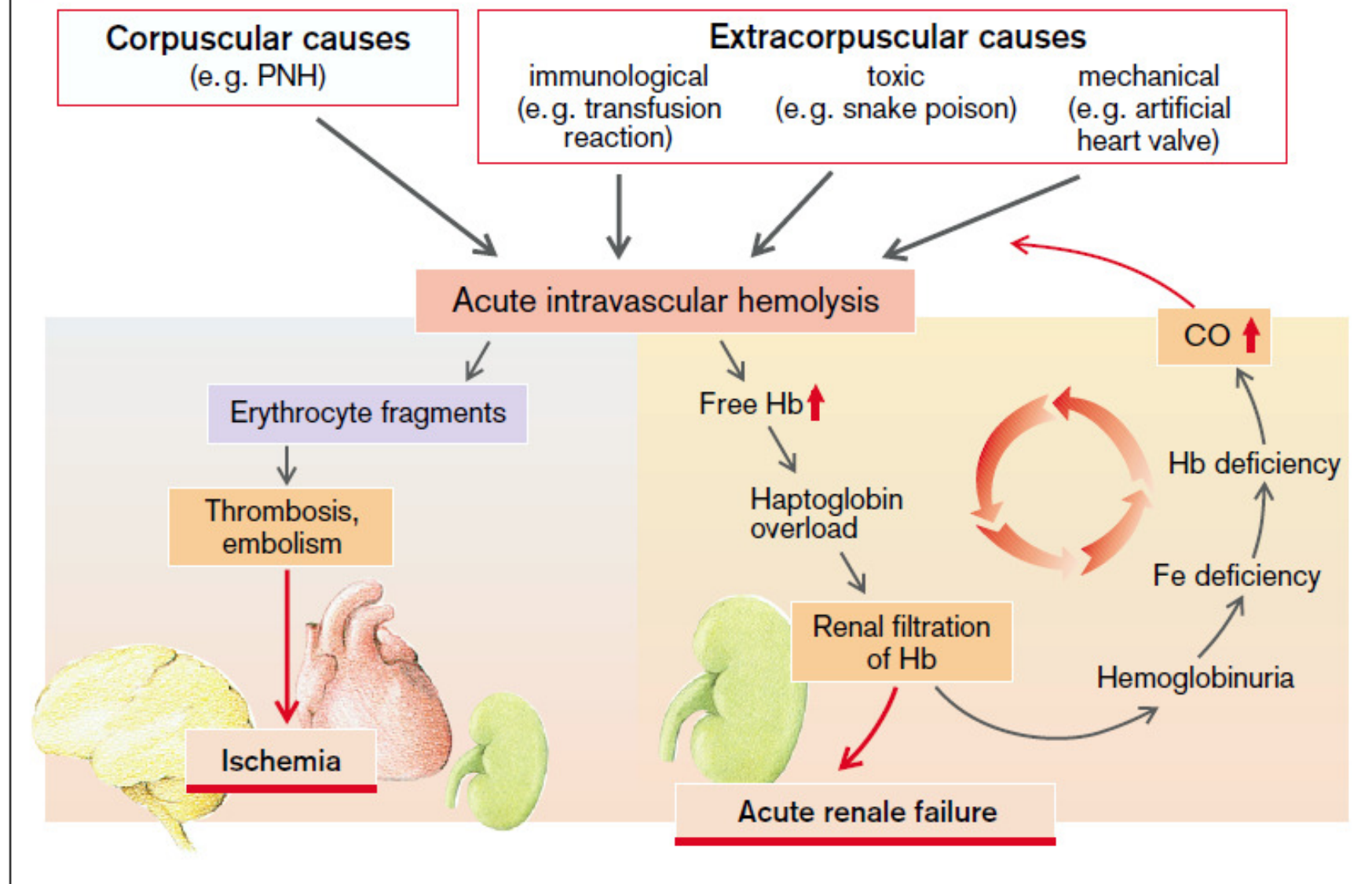
**železo
se nevylučuje
jeho rovnováha
je řízená na
příjmu**



korpuskulární hemolytické anémie

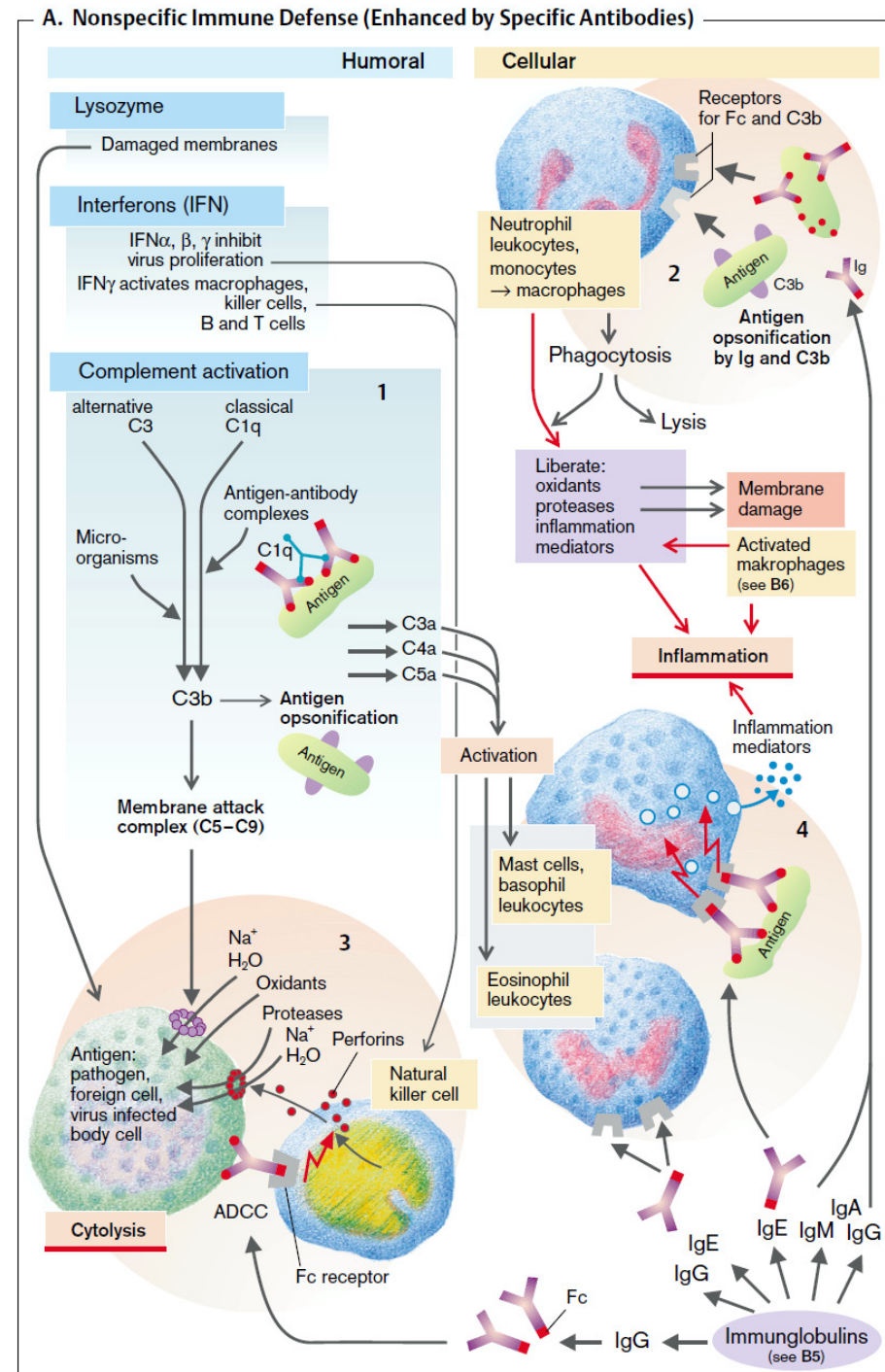
\e/

B. Causes and Consequences of Acute Intravascular Hemolysis

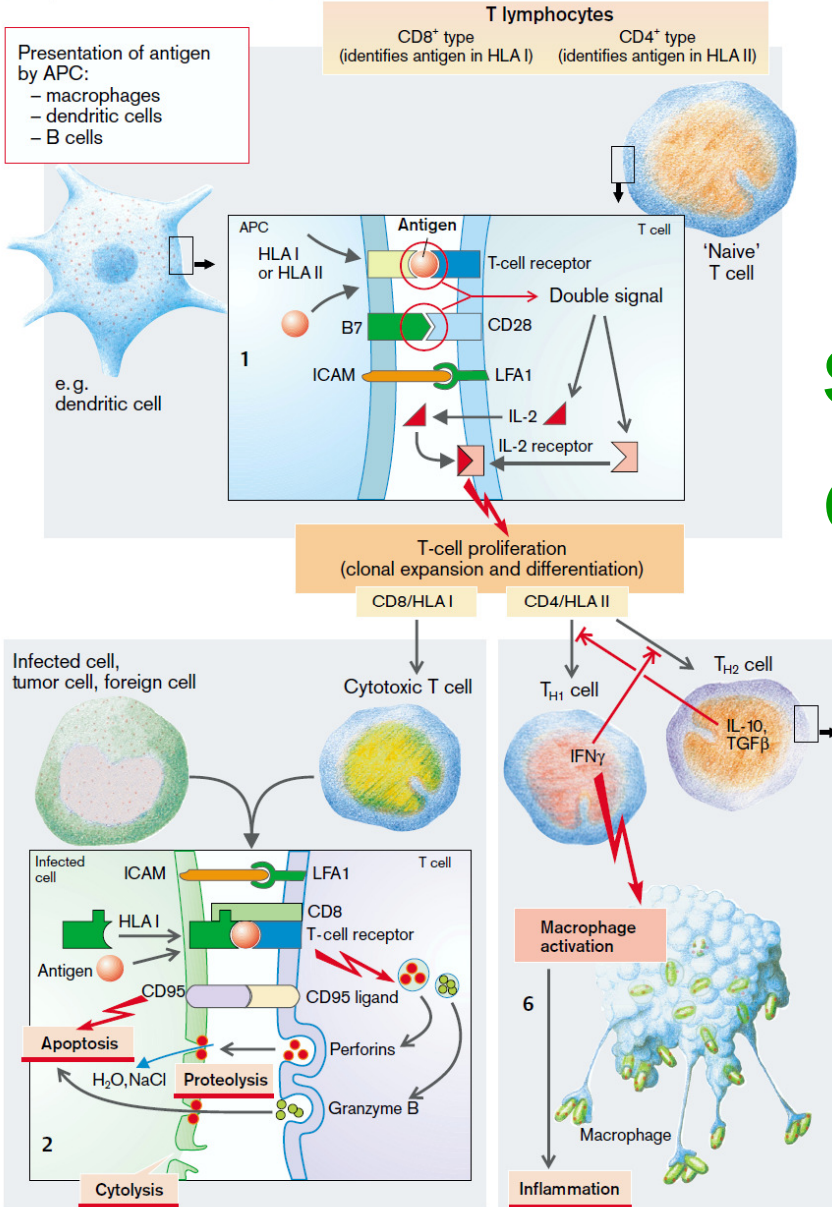


extra-korpuskulární hemolyt. anémie

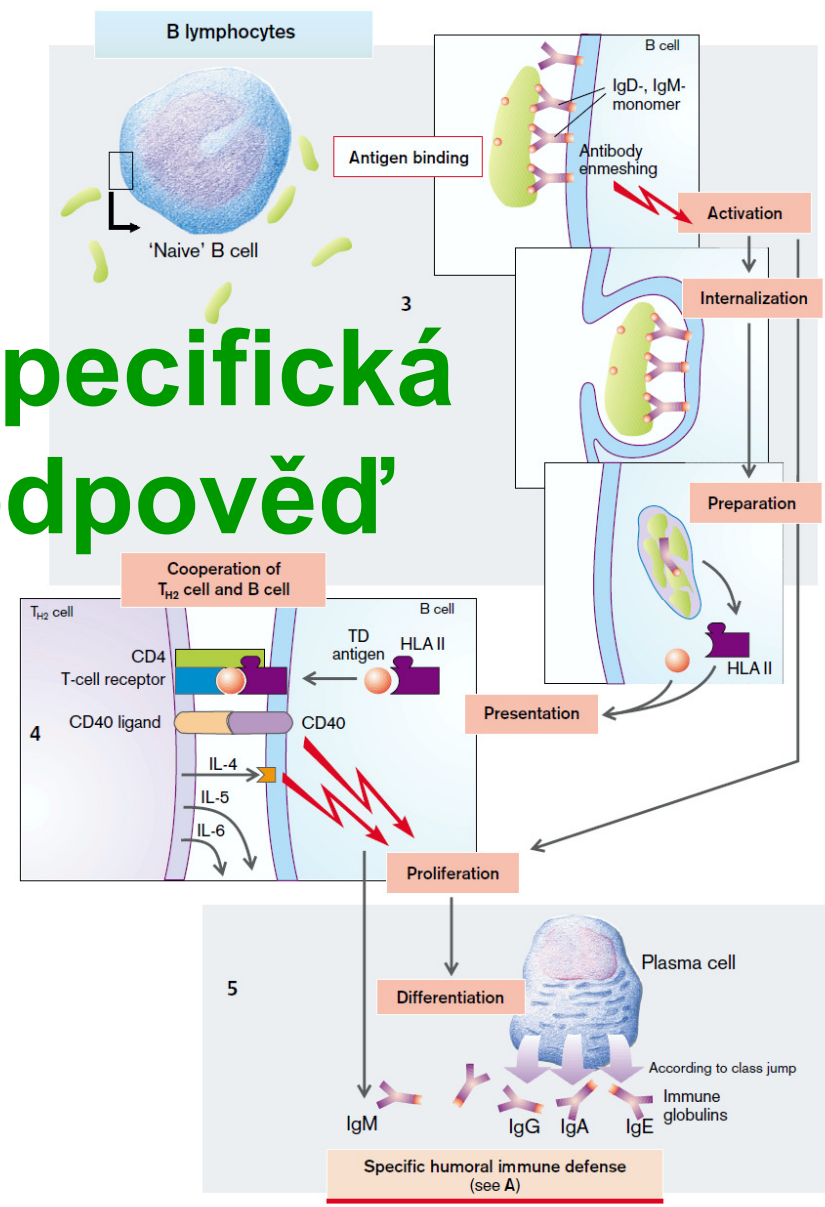
nespecifická látková a buněčná imunitní odpověď



B. Specific Immune Defense



specifická
odpověď



akutní zánět, co jsou to proteiny akutní fáze?

C-reaktivní protein

(reakce s C-polysacharidem streptokoka)

složky komplementu

fibrinogen, protrombin, atd.

plasminogen

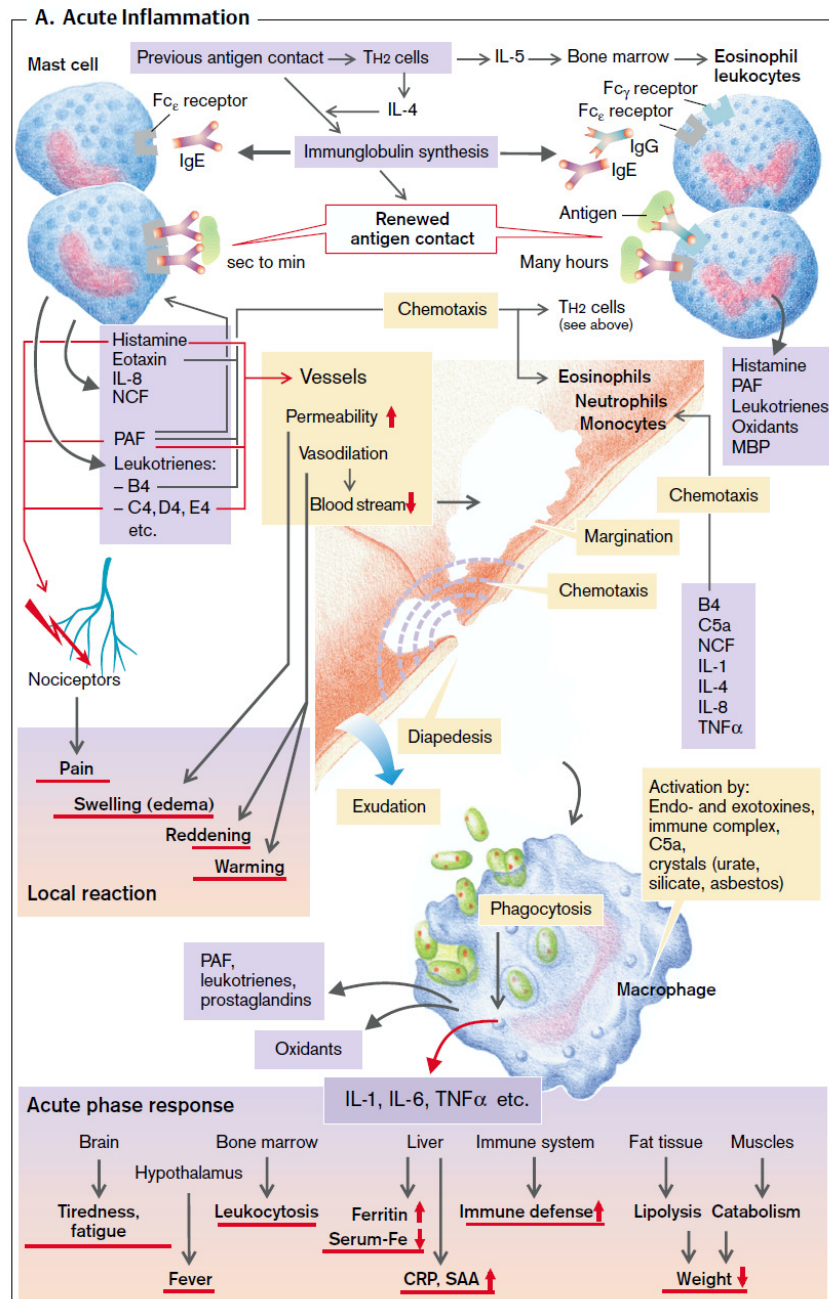
ferritin

hepcidin

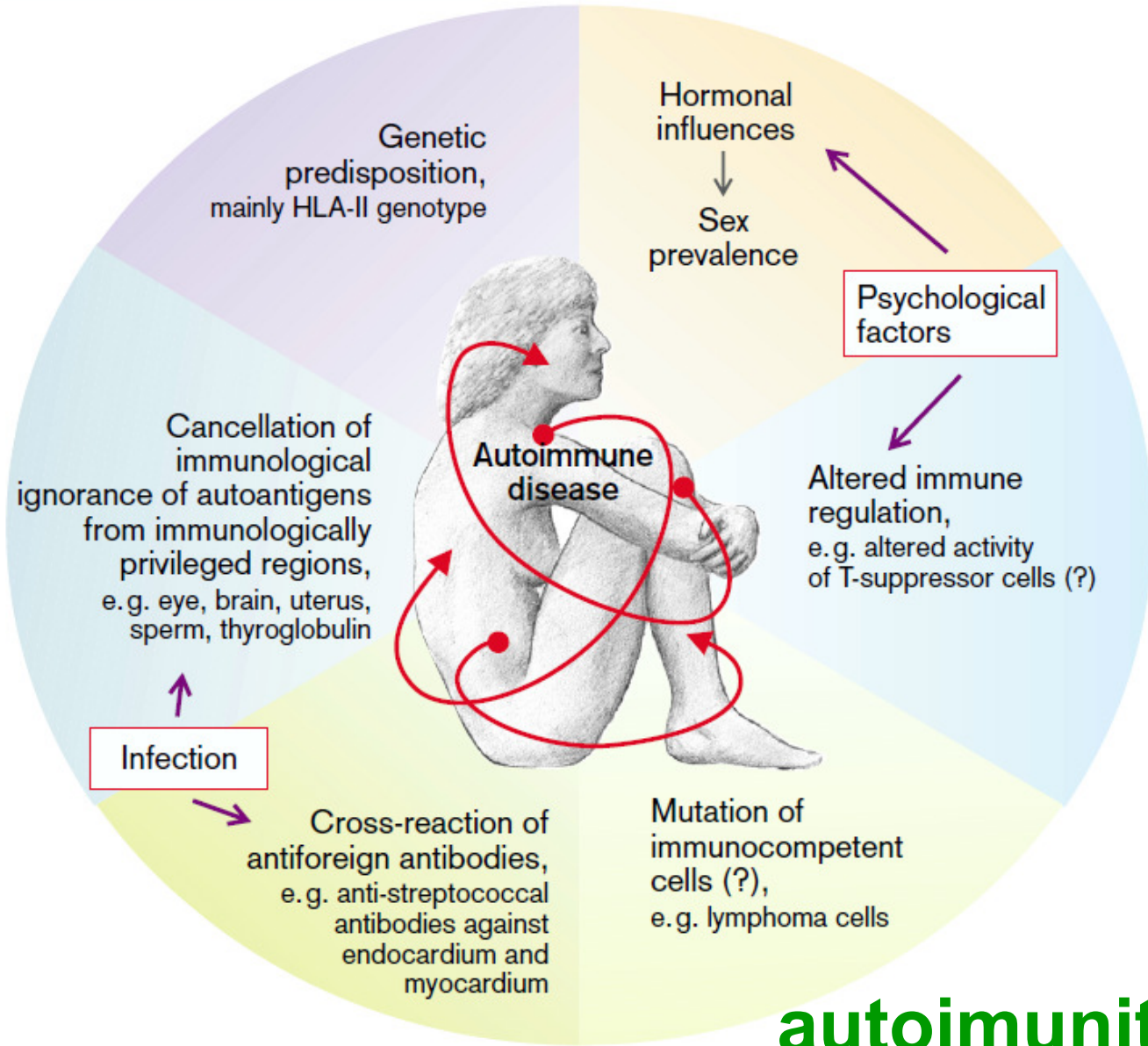
Haptoglobin

alfa-1-anti-trypsin

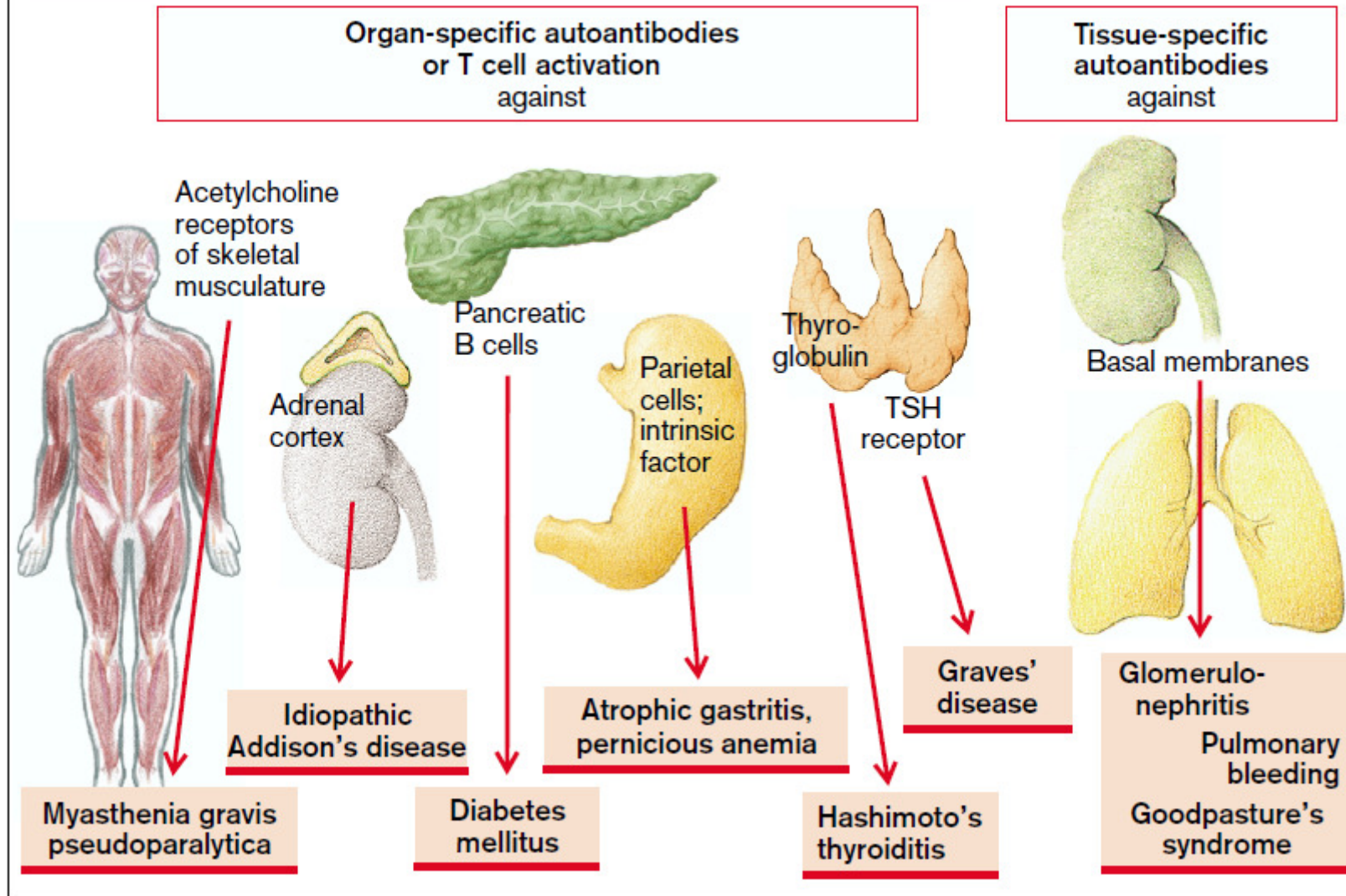
atd.



A. Causes of Autoimmune Disease

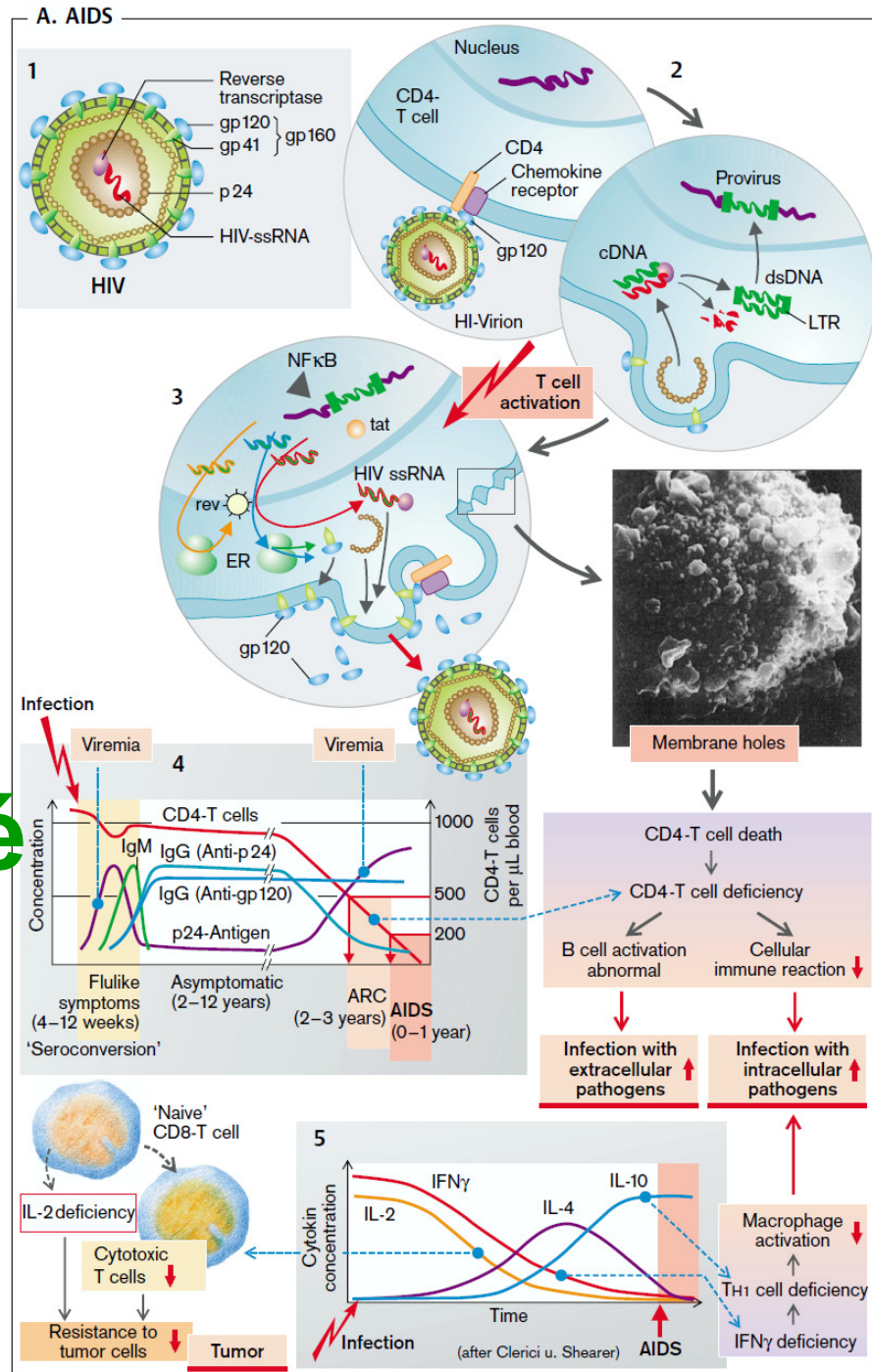


B. Organ-Specific and Tissue-Specific Autoimmune Diseases



autoimmunita

AIDS, syndrom získané imunodeficiency



Blood Components

Upper Gastrointestinal Bleeding

A 30-year-old man, a middle-management executive, consults his physician in a state of panic because for the last 2 weeks his stools have been intermittently black. Although he had considered himself healthy, he in fact has been aware of daily epigastric discomfort and pain over the last 2 years. His distress occurred at first late in the afternoon and more recently also in the middle of the night, awakening him from sleep. He has been relieving the pain by eating food or by taking Tums, tablets of calcium carbonate, but he has taken no other medications. In the past week, the patient has also noticed that he becomes short of breath (dyspneic) when he climbs a flight of stairs. The patient has been under considerable stress at work, he drinks very few alcoholic beverages, but he is a heavy cigarette smoker.

The physician notes that the patient is exceptionally pale; the pallor is most obvious in the conjunctivae and the nail beds. Except for a resting heart rate of 100 beats/min (a slightly high value) and doubtful tenderness on palpation of the epigastrium, the patient's physical examination is unremarkable. Stool obtained by rectal examination is indeed black, and a guaiac test, performed on the stool to check for blood, is positive.

1. An immediate concern is whether the patient's pallor, dyspnea, and marginally elevated heart rate are related to the presence of blood in the stool. To assess this possibility, what laboratory studies would you order immediately?
2. The patient's hematocrit was 21%, hemoglobin was 6 g/dL, and the red blood cell count was 4 million/ μ L. What can you deduce from these values?
3. Hypochromic microcytic anemia is commonplace in patients with chronic blood loss and reflects depletion of the iron stores needed for hemoglobin synthesis. If the patient had lost blood in a single brief event (e.g., had he vomited a substantial amount of blood), the hematocrit would have fallen, but the red blood cells and hemoglobin level would have been reduced in proportion. Because hypochromic microcytic anemia can occur in conditions other than blood loss, several tests could be ordered to confirm the original diagnosis. Which tests might be included?

4. The patient was examined by a gastroenterologist, who pointed out that black stools usually result from bleeding high in the gastrointestinal tract; if the bleeding were from lower in the gastrointestinal tract, the hemoglobin would not have been degraded to a black derivative. The physician postulated that the patient had bled from the peptic ulcer and confirmed this finding by direct visualization of the lesion through a flexible gastroscope. Although tempted to perform a transfusion, the physician instead prescribed medication to treat the ulcer, and ferrous sulfate, to be taken by mouth, to treat the anemia. What was the rationale for this maneuver?
5. How is the efficacy of therapy assessed?

Cellular Membranes and Transmembrane Transport of Solutes and Water

Hereditary Spherocytosis

A 20-year-old woman suffers from anemia and occasional jaundice. A thorough review of her medical records reveals that over the past 10 years she has had episodes of more severe anemia, usually after periods of febrile illness. The patient has a markedly enlarged spleen. Microscopic examination of the patient's blood showed a large number of microspherocytes (red blood cells [RBCs] that are round and somewhat smaller than erythrocytes). The osmotic fragility (measured by putting RBCs in hypotonic solutions) was much greater than that of RBCs from healthy individuals. When the patient's erythrocytes were incubated in a buffer solution at 37° C under sterile conditions, the fraction of the RBCs that were hemolyzed was much larger than the hemolyzed fraction from a healthy individual. This "autohemolysis" could be greatly diminished by including glucose and adenosine triphosphate (ATP) in the RBC incubation solution. RBCs from fresh blood had a normal content of Na^+ and K^+ . The permeabilities of the patient's erythrocyte membranes to Na^+ and K^+ were found to be about three times normal. The level of Na^+ , K^+ -ATPase in the patient's RBC membranes was also about three times the level in RBCs from healthy individuals. The average life span of the patient's erythrocytes was well below the normal life span. When an aliquot of the patient's RBCs was labeled and injected intravenously into a healthy individual, the patient's RBCs had a markedly reduced survival time compared with normal RBCs. When labeled RBCs from a healthy individual were infused into the patient, the survival time of the normal RBCs was comparable with their survival time in the donor. The patient's spleen was removed, and after the splenectomy, the patient's anemia was largely ameliorated.

1. Why should the patient's erythrocytes have a greater osmotic fragility than RBCs from healthy individuals?
2. Why might the patient's RBCs "autohemolyze" more rapidly than normal erythrocytes when they are incubated at 37° C under sterile conditions?
3. Why should including glucose and ATP in the incubation mixture diminish the extent of autohemolysis?
4. Why should the patient's RBCs have a reduced life span? What might the spleen have to do with this?
5. What is proved by the observations that the patient's RBCs have a reduced life span in the circulation of a healthy individual and that the RBCs of a healthy individual have a normal life span in the patient's circulation?
6. Why might the patient have more severe episodes of anemia following febrile illnesses?
7. Why should splenectomy largely correct the patient's anemia?